

Congenital Cardiac Defects in Trisomy 18: A Case Series

Ronak Sheth¹, Kothandam Sivakumar², Bibhas Kar³

How to cite this article:

Ronak Sheth, Kothandam Sivakumar, Bibhas Kar. Congenital Cardiac Defects in Trisomy 18: A Case Series. Indian J Genet Mol Res. 2019;8(1):41-45.

Abstract

Trisomy 18 is the second most common autosomal trisomy after Down syndrome (trisomy 21). Cardiac defects occur in 90% of them. The survival in Edwards syndrome has been uniformly poor with less than 10% patients surviving beyond one year. Traditionally, cardiac interventions and surgery were not pursued in view of the dismal outcomes. We present 3 cases of trisomy 18 seen at our institution over the past 3 years. The series represents the spectrum of cardiac malformations in trisomy 18; from complex cardiac

defects like complete atrio-ventricular (AV) canal defect and Double outlet right ventricle with ventricular septal defect (DORV-VSD) which are only surgically repairable to a simple lesion like patent ductus arteriosus (PDA) which is amenable to transcatheter device closure. Along with supportive medical care, cardiac palliative or corrective interventions may have a role in keeping the child more comfortable and with a better quality of life even if for a short life span.

Keywords: Trisomy 18; Edwards syndrome; Congenital cardiac defects.

Introduction

Trisomy 18 also known as Edwards syndrome is the second most common trisomy syndrome after trisomy 21. The first reported infants were described in 1960 by Edwards [1]. The prevalence in livebirths is estimated as 1/6000-1/8000, but the overall prevalence in the conceptus is higher (1/2500-1/2600) due to the high frequency of fetal loss and medical termination of pregnancy after prenatal diagnosis [2]. The syndrome pattern

consists of major and minor anomalies involving multiple organ systems, pre and post-natal growth retardation and marked psychomotor and cognitive disability. Cardiovascular manifestations are seen in almost 90% of these patients [2]. However traditionally, corrective and palliative cardiovascular procedures are rarely undertaken in view of the "lethal" nature of the syndrome. In this paper we report 3 infants with trisomy 18 presenting with varied congenital cardiac defects.

Author's Affiliation: ¹Fellow, Department of Pediatric Cardiology ²Senior Consultant and Head, Department of Pediatric Cardiology, Institute of Cardiovascular Diseases ³Consultant and Head, Centre for Genetic Studies and Research; The Madras Medical Mission, Chennai, Tamil Nadu 600037, India.

Corresponding Author: Dr. Bibhas Kar, Consultant & Head, Center for Genetic Studies & Research, The Madras Medical Mission, Chennai, Tamil Nadu 600037, India.

E-mail: drbibhaskar65@gmail.com

Received on 11.02.2019; **Accepted on** 27.03.2019

Case Series

Case 1: A two-month-old girl infant, born to non-consanguineous parents by a term caesarean delivery was symptomatic with significant growth failure and recurrent respiratory infections since the first week of life and worsening dyspnea and feeding difficulty.

She was born small for gestational age with a weight of 1.7 kg, length of 46 cm and a head circumference of 33 cm. There was no family history of congenital cardiac defects; no prior reproductive losses were reported in the mother. (Fig. 1A) On admission she was severely under-nourished with a weight of 2.7 kg. The initial clinical examination revealed facial dysmorphism including a prominent wide forehead, wide anterior fontanel, bushy eyebrows with synophrys, small palpebral fissures, ocular hypertelorism, high arched palate, depressed nasal bridge, low-set ears, micrognathia, bilateral clenched hands with over lapping fingers, rocker-bottom feet and penile hypospadias. On neurological examination she had axial hypotonia and poor cephalic control. She had an irregular pattern of hypopigmentation on the right side of the abdomen, not following the Blaschko lines, and a moderate sagittal body asymmetry with left-side muscular hemihypertrophy, particularly evident on the back and lower limbs.

Cardiovascular examination showed a hyperkinetic precordium with cardiomegaly; resting room air saturation of 92%; and grade 2 ejection systolic murmur in pulmonary area. Electrocardiogram reflected a second degree Mobitz type-I AV nodal block with 3:2 AV conduction; right ventricular hypertrophy, with a left axis deviation. Echocardiography showed a complex cardiac defect; DORV with a large routable sub aortic VSD, small patent foramen ovale with left to right shunt, unrestricted pulmonary blood flow and severe pulmonary hypertension.

Case 2: A three-week-old female infant, presented with growth failure, increased effort of breathing and suck-rest-suck cycle. She was second born child to a non-consanguineous couple, born by term normal delivery with a birth weight of 2100 g, length of 45 cm and head circumference 31.5 cm. Family history was unremarkable. (Fig. 1B). On clinical examination she weighed only 2080 g, was lethargic and dyspneic at rest, with facial dysmorphism including low set ears, flat facies, overlapping of index and ring finger over middle finger, and clenched fist and rocker-bottom feet (Fig. 2A).

Cardiovascular examination revealed hyperdynamic precordium with wide fixed split S2 and a grade 4 pansystolic murmur at the left sternal border. Echocardiography showed a

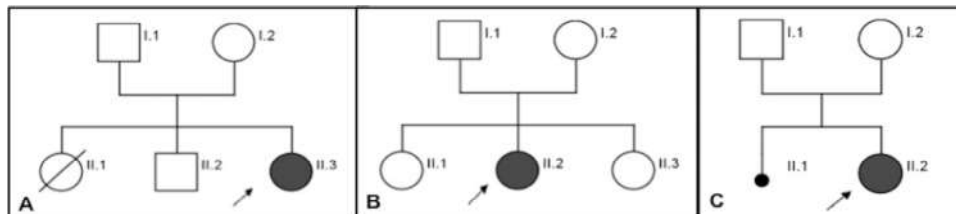


Fig. 1(A, B, C): Pedigree charts of the cases 1, 2 and 3 respectively.

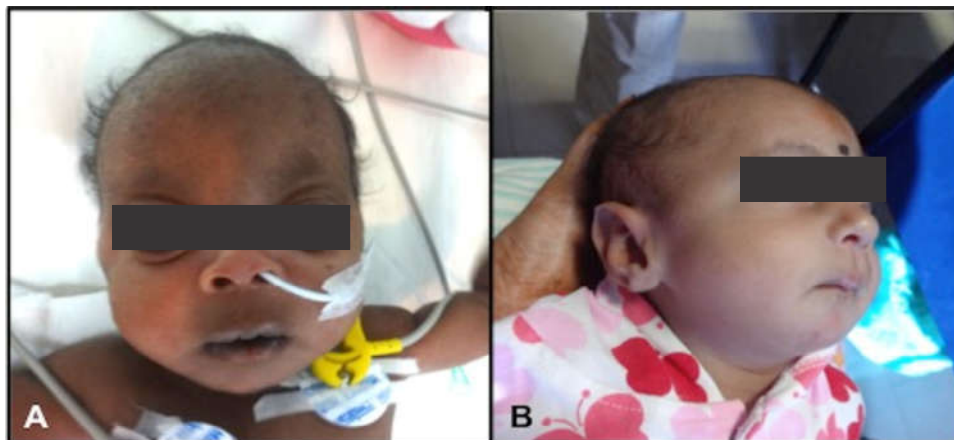

Fig. 2 (A,B): Clinical photographs of Proband case 2 and 3 respectively showing typical dysmorphic features in trisomy 18 - dolicocephaly with tall prominent forehead, small palpebral fissures, low set ears and micrognathia.

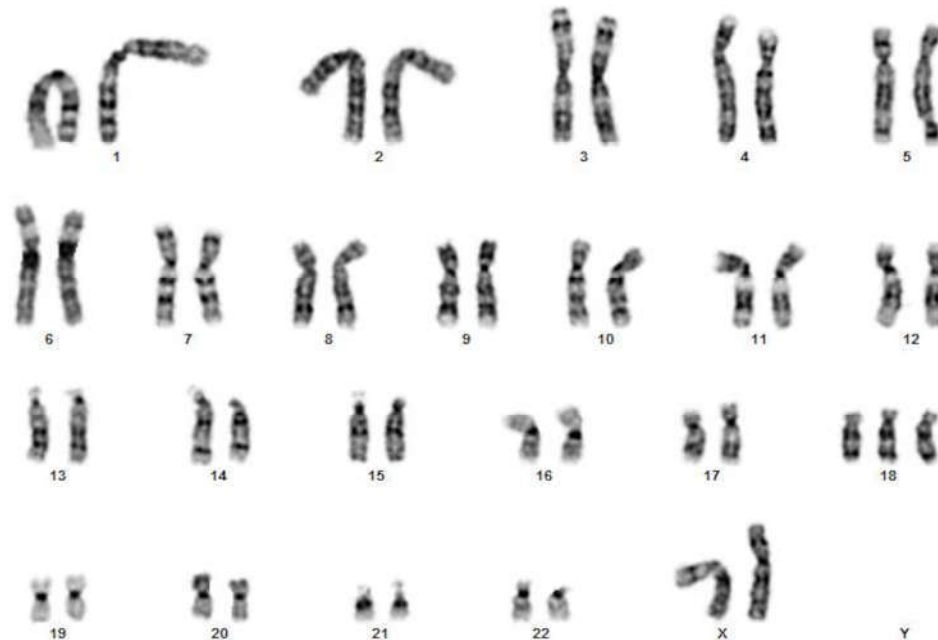


Fig. 3: Karyotype of a proband with 47, XX, +18 chromosomal constitution.

complete atrioventricular septal defect (AVSD) with two well-formed AV valve components and two balanced ventricles, large inlet VSD with subaortic extension, aneurysmal atrial septum with a primum atrial septal defect (ASD) and an additional secundum ASD with left to right shunt, with severe hyperkinetic pulmonary hypertension.

Case 3: This child conceived by in-vitro fertilisation, (Fig. 1C) was born by caesarean section at 35 weeks of gestation with a birth weight of 2.1 kg and had a stormy neonatal course with respiratory distress syndrome and moderate sized PDA requiring mechanical ventilation for 7 days and prolonged oxygen dependence. The child continued to thrive poorly. During a subsequent review, persistent growth faltering and characteristic dysmorphic features including dolichocephaly, prominent occiput, short palpebral fissures, micrognathia, and abnormal pinna (Fig. 2B) prompted a chromosomal analysis, which confirmed the diagnosis of trisomy 18.

Cardiovascular examination revealed no cardiomegaly and no murmur, with a palpable second heart sound and mild lower limb desaturation. Chest radiograph suggested mild peripheral pruning. Echocardiogram showed severe pulmonary hypertension with a bidirectionally shunting PDA suggestive of early pulmonary vascular obstructive disease. She was started on dual pulmonary vasodilator therapy with Sildenafil and Bosentan. She survived two

episodes of bronchopneumonia which needed prolonged oxygen therapy. After the second illness, she was discharged home on oxygen therapy, but succumbed at home a few days later.

Cytogenetic analysis

The lymphocytes from peripheral blood from all the three cases were cultured for karyotyping, and GTG banding was done to identify the chromosome using the nomenclature and chromosome classification of the ISCN, 2009 [3]. The karyotype was found to be 47, XX, +18 suggestive of Edwards syndrome (Fig. 3).

Discussion

Edward syndrome (Trisomy 18) is the second most common chromosomal aneuploidy syndrome and is associated with multisystem involvement. A wide spectrum of cardiovascular anomalies are known in trisomy 18 [4]. Natural history of the syndrome is one of limited survival, 50% live shorter than a week, only about 10% living beyond one year of age [5]. The diagnosis is often prenatal in the developed world; however our series highlights that delayed postnatal diagnosis is still prevalent in the developing world [5]. Thus important decisions in early life including those regarding resuscitation, intensive care management are often taken without the knowledge of the genetic diagnosis. In all

3 cases, significant growth failure and pulmonary hypertension had already set in by the time of genetic diagnosis.

Despite the “uniformly” poor survival in trisomy 18, a wide spectrum of phenotypic expression is known, especially when there is partial or mosaic trisomy 18 [6]. Although almost 90 percent cases have a life expectancy less than 1 year; a small minority may survive even upto two decades.

We cannot predict the survival span of an individual baby with trisomy 18. It is impossible to differentiate a baby with Edwards syndrome who will live only a couple of weeks from that which may go on to live for a couple of decades [7]. Hence, referring to trisomy 18 as a lethal anomaly may be a misrepresentation; and in recent years, a trend towards offering intensive management as well as corrective / palliative cardiac surgeries is emerging [8,9].

In our series, the first two cases required surgical cardiac procedure and after thorough parental counselling, a decision was taken to offer only supportive care. The third child had a lesion amenable to transcatheter closure, and although parents were keen to pursue it, a relatively late diagnosis with very early onset of severe pulmonary vascular disease prevented the cardiac intervention.

Cardiac interventions are likely to modify the natural history of these patients favourably by preventing heart failure and development of pulmonary hypertension, and thus secondarily facilitating discharge from hospital and preventing readmissions; thus improving the quality of life not only of the baby but also of the parents and family members. Amongst the multitude of anomalies and restricted potentials of this chromosomal syndrome, cardiac defects are one of the most correctable and may help to achieve reduction in morbidity.

It is important for the entire medical team to jointly take management decisions in consultation with the parents, giving due importance to parental wishes and concerns and honouring their decisions. Decisions should be made on an individual basis based on the medical issues at hand and the likelihood of the treatment to alleviate suffering in that individual case; rather than based on the genetic diagnosis alone [10-12].

Conclusion

Early diagnosis of Trisomy 18 facilitates collective informed and timely decision making regarding resuscitation, intensive management and cardiac intervention. Palliative and curative cardiovascular interventions and surgery can prevent heart failure and pulmonary hypertension related morbidity; and reduce the number of hospitalisations, facilitate discharge from hospital and may help in improving growth. Despite the poor developmental outcomes in those surviving beyond infancy, early cardiovascular diagnosis and prompt intervention, although may not dramatically improve life expectancy, but would have a definite role in improving the quality of life of these babies and their families.

Acknowledgements

We thank the families of these patients who have cooperated and have agreed to be the part of this scientific publication. We are thankful to the Management of The Madras Medical Mission for providing necessary research facilities.

Abbreviations

ASD - Atrial Septal Defect

AV - Atrio-Ventricular

DORV - Double Outlet Right Ventricle

PDA - Patent Ductus Arteriosus

VSD - Ventricular Septal Defect

Consent

Written informed consent was obtained from the patient for publication of this case report and accompanying images. A copy of the written consent is available for review by the Editor-in-Chief of this journal.

Competing interests

The authors declare that they have no competing interests.

Authors' contributions

SK diagnosed and managed the patient, BK

discussed and analysed the patient data; RS and BK were major contributors in writing the manuscript; all authors have read and approved the final manuscript.

References

1. Edwards JH, Harnden DG, Cameron AH, Crosse VM, Wolff OH: A new trisomic syndrome. *Lancet* 1960;1:787-789.
2. Rasmussen SA, Wong L, Yang Q, May K, Friedman JM: Population-based analyses of mortality in trisomy 13 and trisomy 18. *Pediatrics* 2003;111:777-784.
3. Shaffer LG, Slovak ML. An international system for human cytogenetic nomenclature, ISCN. In: Cambell LJ, editors. S Karger, Basel. 2009.
4. Van Praagh S, Truman T, Firpo A *et al.* Cardiac malformations in Trisomy-18: A study of 41 post-mortem cases. *J. Am. Coll. Cardiol.* 1989;13:1586-97.
5. Cereda and Carey. The trisomy 18 syndrome. *Orphanet Journal of Rare Diseases.* 2012;7:81.
6. Tucker ME, Garringer HJ, Weaver DD. Phenotypic spectrum of mosaic trisomy 18: Two new patients, a literature review, and counseling issues. *Am J Med Genet Part A.* 2007;143A:505-17.
7. Rosa RF, Rosa RC, Zen PR *et al.* Trisomy 18: Review of the clinical, etiologic, prognostic and ethical aspects. *Rev Paul Pediatr.* 2013;31(1):111-20.
8. Kaneko Y, Kobayashi J, Yamamoto Y *et al.* Intensive cardiac management in patients with trisomy 13 or trisomy 18. *Am J Med Genet.* 2008;146A:1372-80.
9. Maeda J, Yamagishi H, Furutani Y *et al.* The impact of cardiac surgery in patients with trisomy 18 and trisomy 13 in Japan. *Am J Med Genet A.* 2011;155A:2641-46.
10. Carey JC. Perspectives on the care and management of infants with trisomy 18 and trisomy 13: striving for balance. *Curr Opin Pediatr.* 2012;24(6):672-78.
11. Fenton LJ. Trisomy 18 and 13: quality of life: treading "softly". *Am J Med Genet A.* 2011;155:1527-28.
12. Janvier A, Okah F, Farlow B, Lantos JD. Ethical Rounds: An infant with trisomy 18 and a ventricular septal defect. *Pediatrics.* 2011;127:754-59.